Stadt Zürich
Stadtspital Triemli

Case Presentation

Urology Arena
Bern, December 1, 2017

Disclaimer

All characters in this presentation (except for myself) are entirely fictional. Any resemblance to actual persons, living or dead, is purely coincidental

Patient

- 60yo female
- PMH:
  Hypertension, mild peripheral artery disease left leg
- Medication:
  Amlodipin 5mg 1-0-1, Valsartan 80mg 1-0-0, Aspirin cardio 100mg 1-0-0
- GP: CT-scan for back pain

- CT-scan of abdomen and chest:

  5.5cm inhomogenous tumor in the lower pole of the right kidney

  Left kidney normal with some simple cysts

  No signs of metastases

- Lab:

  Unremarkable, normal kidney function

CT-scan:

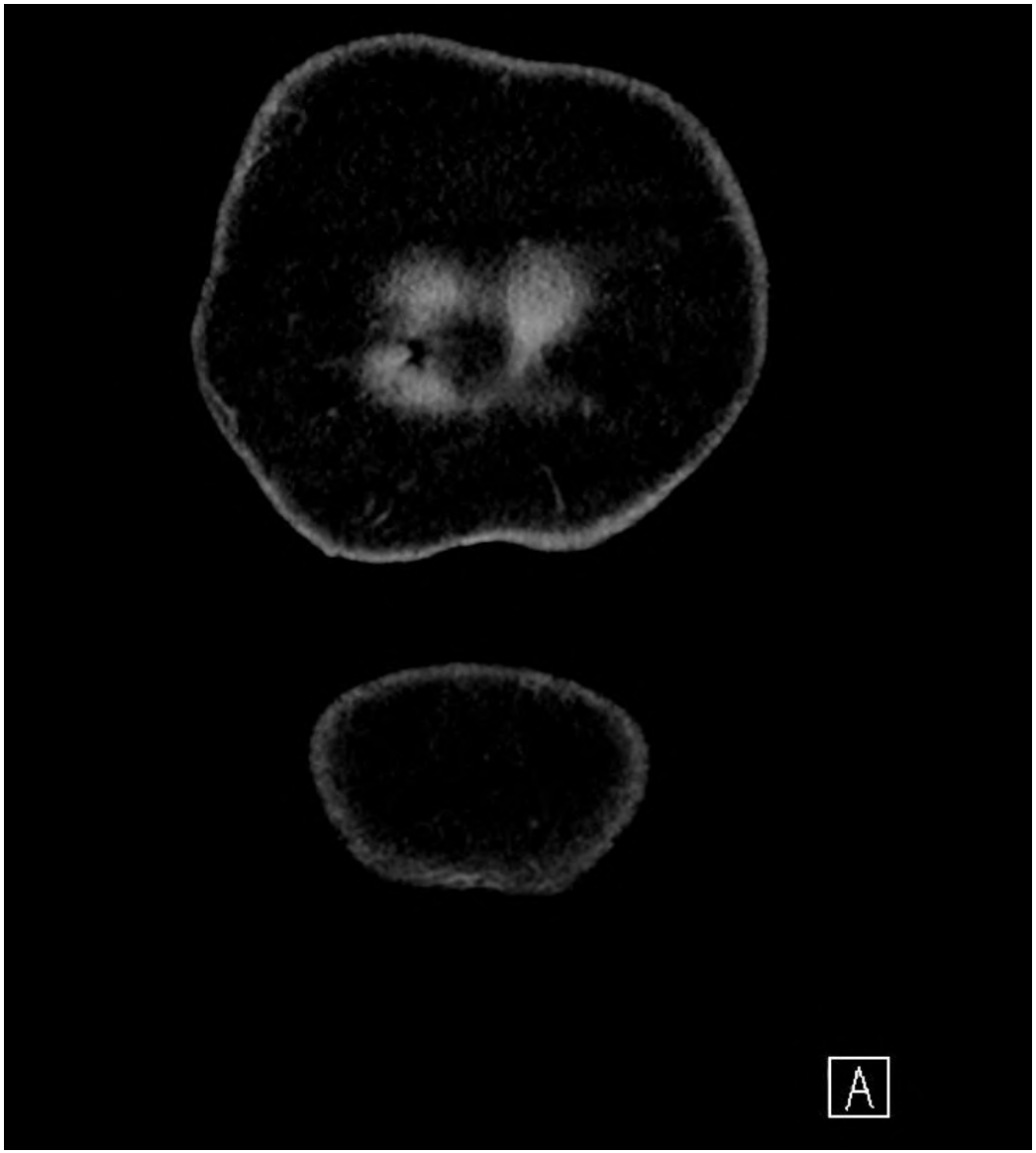

CT-scan:

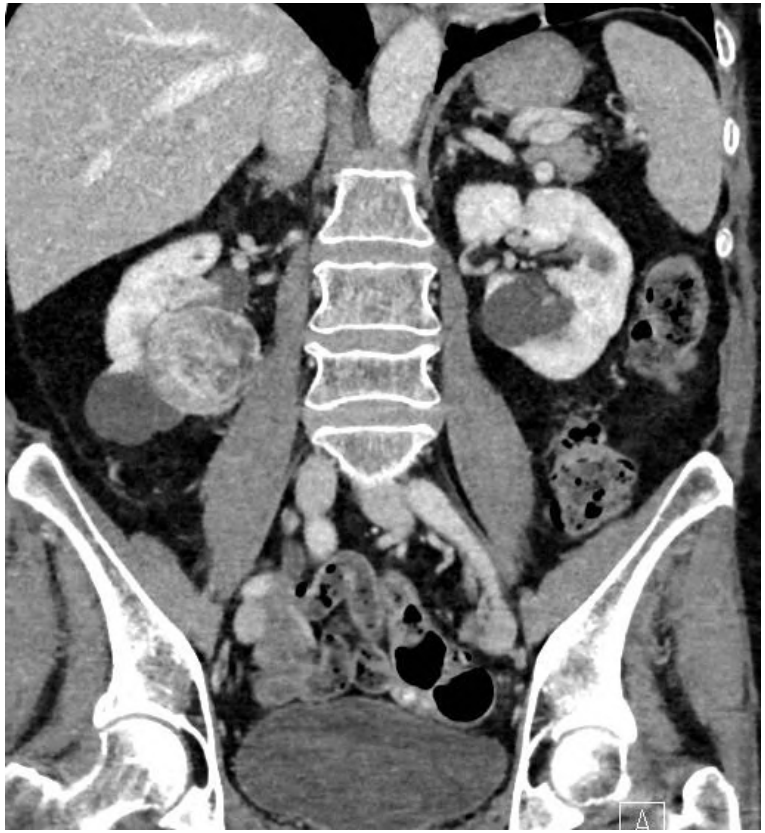

Consultation June 20, 2016

- I advise the patient to resect the tumor
- I advise against a biopsy prior to surgery
- I discuss alternative treatment options (ablative therapies, surveillance)
- I recommend to do a partial rather then a radical nephrectomy

Consultation June 20, 2016

- I recommend a robot-assisted laparoscopic approach
- The patient consents to undergo a robot-assisted laparoscopic partial nephrectomy

Operation July 6, 2016

- Intraoperative course uneventful
- 4h postoperatively the patient develops acute abdominal pain
- CT shows hemorrhage from the resection bed
- Interventional radiology unsuccessfully tries to embolize the bleeding vessel

Postoperative course

- The patient is in hemorrhagic shock
- She is taken back to the OR for emergency laparotomy
- Nephrectomy has to be performed
- 9 units of PRBC are transfused
- The patient stays in the ICU for 3 days

Postoperative course

- The further postoperative recovery is slow but uneventful
- The patient is discharged on postoperative day 15
- Final pathology shows Oncocytoma
- The patient is very unhappy and hires a Lawyer (Mr. Leigh)

Why didn’t I do a biopsy

- In this case biopsy would not have changed my treatment recommendation
- Guidelines recommend biopsy before surveillance, before ablation or before systemic therapy in metastatic disease
- Additionally I do biopsies in case of a secondary tumor or to rule out lymphoma

Why I didn't do a biopsy

- About 10% of renal mass biopsies are 'non-diagnostic'
- Oncocytoma can be very difficult distinguish from chromophobe RCC
- RMB is unreliable in diagnosing oncocytoma
- Tumorresection is an acc for suspected oncocyton

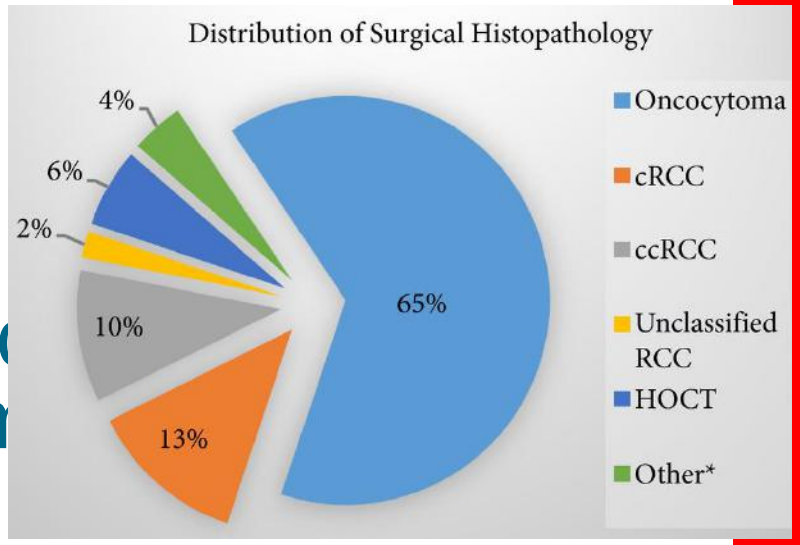

Marconi L, et al Eur Urol 2016
Patel HD, et al BJU Int 2017

Why didn’t I do a radical nephrectomy

- PN yields the same oncologic outcome as RN
- PN preserves renal function better than RN

If I had to do it all over again,

I would do it all over again

Yogi Berra